Case Study

Multimodal Clinical Informatics in Disorders of Sex Development: A Two-Case Study of Diagnostic Integration and Patient-Centered Decision-Making

Nisha Bhaskar Meshram [1*] | Neha Rastogi [2] | Nilesh Nagdeve [3] | Rasika Gadkari [1]

1. Department of Pathology, All India Institute of Medical Sciences (AIIMS), Nagpur, Maharashtra 441108, India
2. Department of Pathology, Kidwai Memorial Institute of Oncology, Bengaluru, Karnataka, India
3. Department of Paediatric Surgery, All India Institute of Medical Sciences (AIIMS), Nagpur, Maharashtra 441108, India

Abstract

Disorders or differences of sex development (DSD) are congenital conditions in which chromosomal, gonadal, anatomical, or endocrine characteristics do not conform to typical patterns of sex development. Evaluating them requires integrating heterogeneous data from clinicians, laboratories, imaging services, surgeons, pathologists, geneticists, psychologists, and patients. This case study examines two patients with atypical external genitalia who demonstrated markedly different underlying biological patterns. Case 1 was a 3-year-old child reared as male with penoscrotal hypospadias, bifid scrotum, asymmetrically positioned gonads, and a 46, XX karyotype. Magnetic resonance imaging did not demonstrate a prostate or seminal vesicles. Laparoscopy identified dysplastic gonads and tubular structures. Histopathology showed seminiferous tubules with absent germ cells in both gonadal samples, a right-sided vas deferens with epididymis, and a left-sided tube with ciliated columnar epithelium and peg cells. WT1 and PAX8 immunohistochemistry supported Müllerian derivation of the left-sided structure. The case was classified as 46, XX testicular DSD with a unilateral Müllerian derivative; ovotesticular DSD could not be excluded. Case 2 was a 19-year-old patient reared as female who presented with primary amenorrhoea, clitoromegaly, a mid-clitoral meatus, labioscrotal folds, and bilateral inguinal gonads. Magnetic resonance imaging showed absent uterus, cervix, and ovaries, a blind-ending vagina, bilateral seminal vesicles, and inguinal testes. Karyotyping was 46, XY, and serum testosterone was 385.4 ng/dL. Bilateral gonadectomy and feminising vaginoplasty were undertaken after counselling and in accordance with the patient's stated gender preference. Histopathology confirmed testes without germ-cell neoplasia. The combined record illustrates why medical informatics is important in DSD: isolated data elements were insufficient, whereas a longitudinal, structured, multidisciplinary record supported diagnosis, risk assessment, shared decision-making, and follow-up planning. It also demonstrates the need for data-quality checks, explicit uncertainty labels, privacy protection, and patient-controlled documentation when managing sensitive lifelong health information.

1. Introduction

Phenotypic sex arises from a precisely coordinated process called sex determination, where the bipotential gonad is directed to develop into either a testis or ovary. This is followed by sex differentiation, in which gonad-produced hormones influence the development of internal ducts and external genitalia **(Rajendiran *et al.* 2021)**. Differences among chromosomal, gonadal, and phenotypic sex lead to disorders of sex development (DSD). The 2006 Chicago consensus updated terminology by replacing outdated terms like intersex, hermaphroditism, and pseudohermaphroditism which were seen as pejorative and inaccurate with a classification based on karyotype into 46, XX DSD, 46, XY DSD, and sex chromosome DSD **(Kim and Kim 2012)**. Genital ambiguity is reported in approximately 1 in 1000 to 1 in 4500 newborns. Congenital adrenal hyperplasia (CAH) is the most common aetiology, followed by androgen insensitivity and mixed gonadal dysgenesis. The presentation is heterogeneous: bilateral non-palpable gonads, scrotal or perineal hypospadias, clitoromegaly, posterior labial fusion, a palpable gonad in an otherwise female perineum, or frank discordance between genital appearance and karyotype **(Krzyscin *et al.* 2025)**. Not every DSD presents with genital ambiguity, but genital ambiguity in a newborn should be treated as a DSD until proven otherwise. Two considerations make early, accurate diagnosis urgent rather than merely desirable **(Wong *et al.* 2023)**. First, salt-wasting CAH is a neonatal emergency and remains the most frequent cause of ambiguity, so 17-hydroxyprogesterone measurement is mandatory in any neonate with atypical genitalia and impalpable gonads. Second, several DSD subtypes, particularly gonadal dysgenesis and partial androgen insensitivity, carry an appreciable risk of germ cell malignancy, which determines the timing of gonadectomy or gonadal biopsy **(Pearce *et al.* 2016)**. Beyond these, the psychosocial burden on the child and family is considerable, and delay compounds it. Karyotype, imaging and hormone profiles narrow the differential but frequently fail to close it. The composition of the gonad itself, and the identity of the ducts that persist alongside it, are morphological questions, and the pathologist becomes a decisive member of the team **(Vasilescu *et al.* 2024)**. We describe two patients who illustrate this point from opposite directions: a 46, XX child reared as male, and a 46, XY adolescent reared as female. From a medical-informatics perspective, these cases are particularly informative because the diagnostic pathway generates heterogeneous data across clinical examination, cytogenetics, laboratory medicine, imaging, laparoscopy, histopathology, immunohistochemistry, counselling, and longitudinal follow-up **(Gangaher *et al.* 2016)**. A useful record should link each observation to its source, date, anatomical site, specimen, interpretation, certainty, and management consequence rather than storing each result as an isolated document **(Hsu *et al.* 2015)**. The objectives of this case study were to reconstruct the clinical and pathological findings of the two patients, examine how multimodal evidence was combined to reach clinically actionable interpretations, and translate the diagnostic pathway into a medical-informatics framework supporting structured documentation, multidisciplinary decision-making, longitudinal surveillance, and safer communication **(AlSaad *et al.* 2024)**. The informatics approach is intended to support specialist judgment rather than replace it.

Received on	:	2026-08-16	**Key Words:**
Revised on	:	2026-10-06	DSD
Accepted on	:	2026-10-17	Clinical informatics
Published Online	:	2026-10-28	Multimodal integration
Review Model	:	Single-Blind Review	Decision support
No. of Reviewers	:	Two	Histopathology
Edited by	:	Dr. Chandrabose Selvaraj	Patient-centred care
Vol and Issue	:	02 (04)	
Page No	:	01-08	
Similarity Level	:	09 %	DOI: 10.64659/jomi/241862
Correspondence	:	Nisha Bhaskar Meshram	**This article is licensed**
Contact Author	:	✉	

©Aayvu Publications Private Limited

2. Materials and Methods

2.1. Study Design and Source Material

This work used a retrospective, descriptive two-case study design. The clinical records of the two patients provided the clinical presentations, imaging findings, karyotypes, hormone data, operative observations, histopathology, immunohistochemistry, interventions, and follow-up information **(Wang *et al.* 2026)**. The analysis was limited to information documented in these records, and no attempt was made to infer unreported molecular results, family history, long-term outcomes, or psychosocial responses **(Merino *et al.* 2024)**.

2.2. Data Extraction and Normalisation

The case document was reviewed section by section. Narrative statements were converted into structured concepts while preserving their original clinical meaning. Anatomical terminology was standardised cautiously **(Crowe *et al.* 2011)**. For example, "right gonad in the labioscrotal fold" and "left gonad in the inguinal region" were recorded as location-specific findings rather than collapsed into a general statement that the gonads were abnormal. Similarly, the right-sided tubular structure was recorded separately from the left-sided structure because their histological identities differed. Laboratory values were retained with their reported units. Case 2 included a serum testosterone concentration of 385.4 ng/dL, FSH of 119 **IU/L**, LH of 54 **IU/L**, 17-hydroxyprogesterone of 30 **ng/mL**, and values of 2.50 ng/mL at baseline and 2.44 ng/mL 60 minutes after. For Case 1, non-visualisation of the prostate and seminal vesicles was recorded as an imaging observation, not as proof that every Wolffian derivative was absent **(Knutsen *et al.* 2026)**. The cystic structure in the left rectovesical region was recorded as a provisional imaging interpretation because hydrometrocolpos was considered but not confirmed. For Case 2, the absence of uterus, cervix, and ovaries, presence of a blind-ending vagina, and presence of seminal vesicles and inguinal testes were captured as separate anatomical observations **(Taweevisit *et al.* 2013)**.

2.3. Diagnostic Synthesis

The diagnostic synthesis followed a multimodal reasoning model. First, chromosomal data were compared with external phenotype. Second, imaging and operative findings were used to map internal structures. Third, hormonal data were interpreted in relation to gonadal and ductal anatomy **(Lafta *et al.* 2024)**. Fourth, histopathology was used to establish the tissue composition and identity of the gonads and tubular structures. Fifth, immunohistochemistry was considered as confirmatory lineage evidence where available. Finally, management decisions were linked to the patient's age, gender of rearing or stated preference, malignancy considerations, reproductive anatomy, and need for endocrine follow-up **(Abushaala *et al.* 2021)**. The synthesis distinguished observation from interpretation. "Seminiferous tubules lined predominantly by Sertoli cells" was treated as a pathological observation. "Testicular tissue" was treated as a tissue-level interpretation supported by that observation. "Partial androgen insensitivity syndrome" was treated as the clinical diagnosis reported for Case 2, supported by the combined pattern of 46, XY karyotype, testosterone in the male reference range, absent Müllerian structures, preserved Wolffian derivatives, incomplete external masculinisation, and testicular histology. Because androgen-receptor sequencing was not performed, the molecular cause remained unconfirmed **(Jensen *et al.* 2022)**.

2.4. Informatics Modelling

For the informatics analysis, a conceptual longitudinal patient record was designed around a common clinical event model. Each event would contain a patient identifier, encounter date, service, specimen or anatomical site, observation, result, unit where applicable, interpretation, responsible professional, confidence level, and linked management action **(Wang and Zuo 2022)**. The model would support relationships such as "laboratory result supports diagnosis," "specimen obtained during procedure," "image describes anatomical site," and "management decision follows multidisciplinary counselling." A diagnostic timeline was then constructed for each case. The timeline began with the presenting concern, followed by clinical examination, investigations, operative assessment, pathological interpretation, multidisciplinary counselling, intervention or surveillance, and planned follow-up **(Taberna *et al.* 2020)**. A comparison matrix was used to identify which findings were shared by the two cases and which were discriminating. Potential decision-support rules were written as human-readable prompts rather than automated diagnoses. Examples include prompting urgent assessment for congenital adrenal hyperplasia in a neonate with atypical genitalia, prompting review of gonadal malignancy risk when dysgenetic or testicular tissue is documented, and prompting molecular confirmation when a clinical diagnosis remains syndromic but unsequenced **(Speiser *et al.* 2010)**.

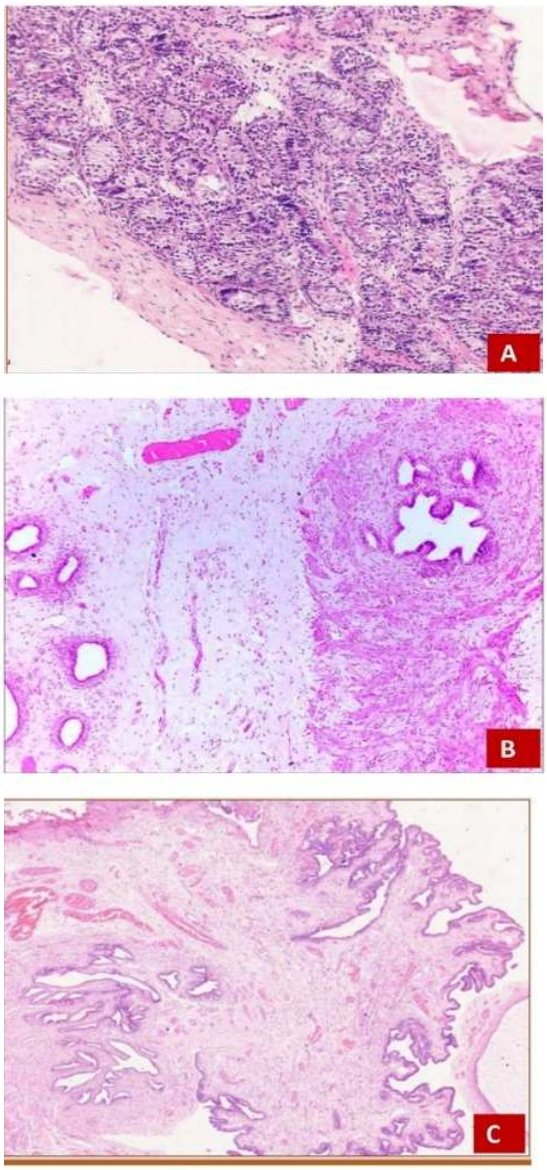

Figure 1. Case 1 — 46,XX DSD. (A) Gonadal biopsy showing lobules of seminiferous tubules lined predominantly by Sertoli cells; germ cells are not identified (H&E, ×10). **(B)** Right-sided tubular structure showing vas deferens (H&E, ×2). **(C)** Left-sided tubular structure showing mucosal plicae lined by tall columnar ciliated epithelium, consistent with Müllerian (tubal) derivation; Müllerian derivation was supported by WT1 and PAX8 immunohistochemistry (H&E, ×2).

2.5. Data-Quality and Ethical Safeguards

Data-quality review focused on missingness, ambiguous units, internal discordance, and terminology. The absence of molecular testing was classified as a documented limitation. The possible mismatch between the initial clinical label and strict tissue-based terminology for ovotesticular DSD was classified as a nomenclature issue requiring specialist review rather than silently corrected **(Syryn *et al.* 2023)**. The endocrine values with incompletely specified analytes were flagged as incomplete observations. Because the cases involve highly sensitive information, the proposed informatics workflow requires de-identification for secondary use, minimum-necessary access, audit trails, encryption, and separation of clinical identity from research datasets **(Sim *et al.* 2023)**. Any future use for model development would require governance approval, consent or an appropriate waiver, and safeguards against re-identification. Patient-reported gender identity and preferences should be recorded respectfully and should not be treated as diagnostic variables. The final interpretation should remain clinician-led and patient-centred.

3. Case Presentation and Results

3.1. Case 1: 46, XX Testicular DSD

A 3-year-old child, assigned and reared as male since birth, was referred for evaluation of abnormal external genitalia.

Clinical examination: Penoscrotal hypospadias with a bifid scrotum was noted. The phallic structure measured 3.5 cm. The right gonad was palpable in the labioscrotal fold and the left gonad in the inguinal region.

Imaging: Magnetic resonance imaging (MRI) of the abdomen and pelvis showed non-visualisation of the prostate and seminal vesicles. A cystic structure in the left rectovesical region raised the possibility of hydrometrocolpos.

Cytogenetics: Peripheral blood karyotype was 46, XX; *SRY* status was not determined.

Hormonal profile: Hormonal studies were not performed before laparoscopy.

Surgical findings: Diagnostic laparoscopy showed bilateral dysplastic gonads with tube-like structures. No, grossly recognizable Müllerian structures and no vas deferens were identified at laparoscopy. Wedge biopsies were taken from both gonads and from both tubular structures.

Histopathology: Sections from both gonads showed lobules of seminiferous tubules lined predominantly by Sertoli cells; germ cells were not identified. No ovarian stroma, primordial follicles or oocytes were identified. The right-sided tubular structure showed a thick muscular wall and stellate lumen characteristic of the vas deferens, with an adjacent portion of epididymis. The left-sided structure showed plicated mucosal folds lined by tall columnar ciliated epithelium with intercalated (peg) cells, reproducing the morphology of a fallopian tube. The epithelium was immunoreactive for WT1 and PAX8, which, together with the morphology, supported Müllerian derivation **(Figure 1)**.

Diagnosis: The case was initially labelled clinically as ovotesticular DSD. However, ovotesticular DSD requires histological demonstration of both ovarian tissue containing follicles and testicular tissue in the same individual, and only testicular tissue was demonstrated in either gonadal biopsy **(Lee *et al.* 2006; Syryn *et al.* 2023)**. The case is therefore classified as 46, XX testicular DSD with undetermined *SRY* status. Ovotesticular DSD cannot be excluded, because the biopsies sampled only part of each gonad and the persistence of a Müllerian-derived tube on the left suggests reduced local anti-Müllerian hormone (AMH) exposure on that side, as is typically seen adjacent to an ovotestis. Management involved postponing gonadectomy due to the diagnostic complexity and the irreversible nature of gonadal surgery. This approach allowed the child to be involved in making decisions regarding gender rearing and surgery when he reached an age of understanding. The family was provided with structured counselling, and the child was enrolled in ongoing multidisciplinary follow-up, which included periodic clinical and radiological monitoring of the retained gonads.

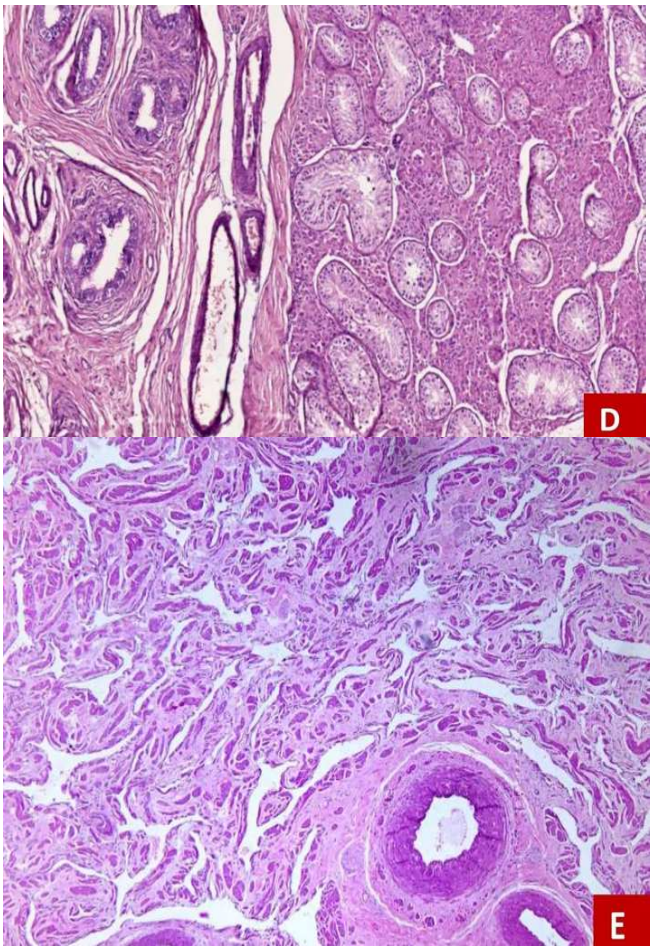

Figure 2. Case 2 — Partial androgen insensitivity syndrome. (D) Bilateral gonads showing seminiferous tubules, epididymis and vas deferens, consistent with testicular tissue (H&E, ×4). **(E)** Corpora cavernosa (H&E, ×10).

3.2. Case 2: 46, XY DSD with a Clinical Diagnosis

A 19-year-old patient reared as female presented with primary amenorrhoea, absent breast development, increased facial hair, and deepening of the voice.

Clinical examination: There was clitoromegaly with a meatal opening at the mid-clitoral level, labioscrotal folds, and bilaterally palpable gonads in the inguinal regions.

Imaging: MRI of the pelvis demonstrated an absent uterus, cervix and bilateral ovaries, with a blind-ending vagina. Bilateral seminal vesicles and bilateral inguinal testes were identified.

Hormonal profile: Serum testosterone was 385.4 ng/dL. FSH was 119 **IU/L**, LH was 54 **IU/L**, and 17-hydroxyprogesterone (17-OHP) was 30 **ng/ml**. Serum 17-hydroxyprogesterone (17-OHP) 2.50 ng/mL at baseline and 2.44 ng/mL 60 minutes after **following a synthetic ACTH 250mcg dose by IM**.

Cytogenetics: Karyotype was 46, XY.

Management: After detailed counselling, and in keeping with the patient's stated gender identity and preference, bilateral gonadectomy with feminising vaginoplasty and clitoroplasty was performed.

Histopathology: Both gonads showed seminiferous tubules, epididymis, and vas deferens, with morphology entirely consistent with testicular tissue. Sections from the phallic structure showed corpora cavernosa. No ovarian tissue and no germ-cell neoplasia were identified **(Figure 2).**

Table 1: Clinical, imaging, cytogenetic, histopathological and management comparison of the two cases

Clinical domain	Case 1	Case 2
Age / gender of rearing	3 years, male	19 years, female
Presenting complaint	Atypical external genitalia	Primary amenorrhoea
External phenotype	Penoscrotal hypospadias; bifid scrotum; phallic structure 3.5 cm	Clitoromegaly; mid-clitoral meatus; labioscrotal folds
Gonadal position	Right labioscrotal; left inguinal	Bilateral inguinal
Karyotype	46, XX	46, XY
Key imaging	Prostate and seminal vesicles not visualised; left rectovesical cystic structure considered for hydrometrocolpos	Absent uterus, cervix and ovaries; blind-ending vagina; seminal vesicles and inguinal testes present
Gonadal histology	Seminiferous tubules with predominantly Sertoli cells; germ cells not identified	Seminiferous tubules with epididymis and vas deferens; unequivocal testicular tissue
Ductal findings	Right: vas deferens + epididymis. Left: ciliated tubal-type epithelium; WT1/PAX8 support Müllerian derivation	Wolffian derivatives present; bilateral seminal vesicles
Hormonal data	Not performed before laparoscopy	Testosterone 385.4 ng/dL; FSH 119; LH 54; 17-OHP 30; two additional incompletely specified values
Integrated diagnosis	46, XX testicular DSD with unilateral Müllerian derivative; ovotesticular DSD not excluded	Partial androgen insensitivity syndrome (clinical); molecular confirmation not performed
Intervention / follow-up	Gonadectomy deferred; multidisciplinary surveillance and counselling	Bilateral gonadectomy and feminising vaginoplasty; oestrogen replacement and endocrine/psychological follow-up

17-OHP, 17-hydroxyprogesterone; DSD, difference/disorder of sex development; FSH, follicle-stimulating hormone; LH, luteinising hormone. Units for FSH, LH and 17-OHP are to be confirmed by the authors.

Diagnosis: The integrated clinical, biochemical, radiological, cytogenetic, and histopathological pattern supported a clinical diagnosis of partial androgen insensitivity syndrome (PAIS). Molecular confirmation by *AR* gene sequencing was not performed, and 5α-reductase type 2 deficiency and 17β-hydroxysteroid dehydrogenase type 3 deficiency were not excluded biochemically; the diagnosis is therefore reported as clinical rather than molecularly confirmed.

Outcome: The postoperative course was uneventful. Oestrogen replacement was initiated to support endocrine health and bone preservation, and ongoing endocrine and psychological follow-up was arranged.

3.3. Comparative Summary of the Two Cases

The two cases shared atypical external genital development but differed substantially in chromosomal, internal anatomical, gonadal, hormonal, pathological, and management findings **(Table 1)**.

4. Comparative Analysis

The two cases show why DSD diagnosis cannot be reduced to one test or one anatomical observation. In Case 1, the 46, XX karyotype did not predict the presence of bilateral seminiferous tubules, and the external male phenotype did not reveal the asymmetrical coexistence of a vas deferens on one side and a Müllerian-derived tube on the other. In Case 2, the 46, XY karyotype and male-range testosterone did not produce typical male external anatomy. Diagnostic value emerged from the pattern formed by all modalities together. In Case 1, histopathology was the most discriminating evidence. Gonadal microscopy established testicular-type differentiation, while ductal microscopy identified side-specific developmental divergence. WT1 and PAX8 staining supported a Müllerian-derived lineage. The absence of germ cells in sampled seminiferous tubules was clinically relevant but cannot be treated as proof that germ cells are absent from every part of either gonad. Case 2 followed a different diagnostic logic. The absent uterus and cervix indicated effective Müllerian-inhibiting activity, while seminal vesicles and testes confirmed Wolffian and testicular differentiation. Male-range testosterone with incomplete external masculinisation shifted the diagnostic focus toward androgen action rather than testosterone production alone. Histology confirmed testicular tissue and excluded ovarian tissue and germ-cell neoplasia in the examined specimens, but did not by itself prove an androgen-receptor mutation. Important uncertainties remain visible in both records. *SRY* testing and broader genomic analysis were not performed for Case 1, and *AR* sequencing was not performed for Case 2. The Case 2 hormone panel contained incompletely labelled values, and the possible hydrometrocolpos described on imaging in Case 1 was not confirmed. These uncertainties should be retained as explicit data-quality states rather than silently resolved.

5. Medical Informatics Analysis

The cases illustrate a classic multimodal clinical-informatics problem: high-value information is distributed across clinical examination, laboratory systems, radiology reports, operative notes, pathology reports, immunohistochemistry, genetic testing, and narrative counselling documentation. If these sources remain disconnected, clinicians may see a karyotype without the tissue diagnosis, an image without the pathology, or a surgical decision without the patient's stated preferences. A longitudinal DSD record should therefore provide a unified timeline linking each finding to its source, date, anatomical location, specimen, interpretation, certainty, and clinical consequence. A useful data model should represent phenotype, gender of rearing, patient preference, anatomy, gonads, ducts, laboratory results, imaging, specimens, histological observations, immunohistochemistry, genetic tests, procedures, counselling encounters, and follow-up plans as separate but linked entities. Each result should retain provenance **(Table 2)**.

5.1. Decision Support and Uncertainty

Clinical decision support could assist without making an autonomous diagnosis. Rule-based prompts may identify the need for urgent endocrine evaluation in a neonate with atypical genitalia, prompt documentation of 17-hydroxyprogesterone and electrolyte assessment when congenital adrenal hyperplasia is a concern, and remind clinicians

Table 2: Proposed minimum data structure for a longitudinal DSD clinical-informatics record

Data domain	Core data elements	Informatics requirement	Clinical purpose
Phenotype & rearing	External genital findings; gender of rearing; patient preference	Structured, time-stamped, respectful terminology	Phenotype description and patient-centred planning
Anatomy & imaging	Gonadal position; uterus/cervix/vagina; Wolffian/Müllerian structures	Side-specific mapping; distinguish absent, not visualised and indeterminate	Anatomical synthesis and operative planning
Laboratory & cytogenetics	Karyotype; testosterone; FSH; LH; 17-OHP; molecular tests	Units, reference intervals, specimen, timing and test status	Diagnostic interpretation and identification of missing evidence
Pathology & IHC	Gonadal tissue; ducts; germ cells; neoplasia; WT1/PAX8	Specimen provenance; anatomical side; linked images and interpretation	Tissue identity, malignancy assessment and diagnostic refinement
Procedures & counselling	Laparoscopy; gonadectomy; vaginoplasty; counselling	Link decision to indication, evidence and patient preference	Traceable multidisciplinary decision-making
Follow-up & governance	Surveillance; endocrine care; access history	Longitudinal timeline, role-based access, audit trail and de-identification	Continuity, privacy and safer transitions

17-OHP, 17-hydroxyprogesterone; FSH, follicle-stimulating hormone; IHC, immunohistochemistry; LH, luteinising hormone.

to document gonadal location, internal anatomy, karyotype, hormone values, and family counselling. When testicular or dysgenetic tissue is recorded, the system could prompt review of malignancy risk, surveillance planning, and adequacy of pathology sampling. The system should also support uncertainty-aware reporting. A positive result, negative result, non-visualized structure, provisional interpretation, and unperformed test are different states and should not be represented by the same field. Case 1 demonstrates the importance of distinguishing 'not seen at laparoscopy' from 'absent on histology'. Case 2 demonstrates the need to distinguish a clinical diagnosis of PAIS from a molecularly confirmed *AR* variant.

5.2. Interoperability, NLP, and Governance

Natural-language processing (NLP) could extract relevant findings from pathology and radiology reports, but it should display extracted concepts for human verification. A future registry could use controlled terminology for anatomical structures, specimen sites, histological patterns, endocrine measurements, procedures, and follow-up outcomes. Interoperability would be improved by mapping local terms to recognised clinical and laboratory vocabularies while retaining the original report text. Privacy and governance are essential. Access should be role-based, with separate permissions for clinical care, research, pathology images, genetic data, and patient-facing summaries. Every access event should be auditable. Research datasets should be de-identified, and rare combinations of age, anatomy, karyotype, and pathology should be assessed for re-identification risk. Patient-facing records should use respectful language, accurately record preferences, and avoid exposing sensitive historical information beyond what is necessary for care.

6. Discussion

The causes of ambiguous genitalia can be grouped into:

1) 46, XX DSD, often due to virilisation of a female fetus from excess androgens, whether from internal sources such as CAH or external sources.

2) 46, XY DSD, resulting from under-virilisation of a male fetus due to issues such as defective androgen synthesis, impaired conversion to dihydrotestosterone, or impaired androgen action.

3) Ovotesticular DSD.

4) sex chromosome DSD types, such as 45,X/46, XY mosaicism, 47,XXY, and 45,X; and 5) maternal androgen exposure. Among these, CAH caused by 21-hydroxylase deficiency is the most common and the only one that can lead to neonatal death.

Both of our patients illustrate how far the external phenotype can diverge from the underlying genotype. Case 1 had a 46, XX karyotype and was reared as male; Case 2 had a 46, XY karyotype and was reared as female. Neither karyotype nor imaging alone would have been sufficient.

6.1. Case 1: 46, XX DSD with Testicular Tissue

About 60% of patients with ovotesticular DSD are 46, XX. Around one-third exhibit mosaic or chimeric karyotypes, such as 45, X/46, XY or 46, XX/47,XXY, while approximately 7% are 46, XY. Testis development in a 46, XX individual is typically explained by translocation of the *SRY* gene onto an X chromosome or an autosome. However, *SRY*-negative cases also occur and are linked to gain-of-function mutations in downstream testis-promoting genes like *SOX9* duplication, or to loss of ovary-promoting pathways such as *RSPO1*/*WNT4*/β-catenin. The child's histological findings are notable for their internal discordance. Although bilateral testicular tissue suggests that Sertoli cells produced anti-Müllerian hormone (AMH), the persistence of a Müllerian-derived tube on the left indicates that AMH's local effect was inadequate on that side. Such asymmetry—a vas deferens on one side and a fallopian tube on the other—is characteristic of gonads with incomplete or heterogeneous testicular differentiation, representing a morphological feature rather than a hormonal one. We identified the left tubular structure as Müllerian in origin due to its tall columnar ciliated epithelium with intercalated cells, supported by WT1 and PAX8 immunolabelling. Interestingly, laparoscopy had not detected a vas or Müllerian structures. The lack of germ cells in the seminiferous tubules is another important prognostic factor. Germ cell depletion often occurs in dysgenetic gonadal tissue, and although this suggests limited fertility potential, it does not eliminate the risk of germ cell neoplasia in situ in individuals with testis-determining tissue. Therefore, ongoing surveillance is recommended.

6.2. Case 2: Partial Androgen Insensitivity Syndrome

Androgen insensitivity syndrome is an X-linked condition caused by mutations in the androgen receptor (AR) gene, with an incidence of approximately 1 in 130,000 births. The phenotype reflects varying levels of residual receptor function, ranging from complete AIS with unmistakably female external genitalia to partial AIS with ambiguous genitalia, and mild AIS where genitalia are mostly male, often accompanied by infertility or gynaecomastia. Clinical presentations include unilateral or bilateral inguinal hernia, primary amenorrhoea, and discordance between karyotype and phenotypic sex. In our patient, the

findings formed a coherent pattern once integrated: a 46, XY karyotype, testosterone within the male range, absent Müllerian structures (indicating effective AMH secretion by functional Sertoli cells), and preserved Wolffian derivatives such as the seminal vesicles (indicating some androgen effect on the ducts), together with incompletely masculinised external genitalia and a blind-ending vagina. This pattern (normal or high testosterone with under-developed external genitalia and intact Wolffian structures) is typical of a problem with the body's response to hormones, rather than a problem with hormone production itself. The main alternative diagnoses need to be explicitly stated because they are clinically and prognostically different and are often confused. 5α-reductase type 2 deficiency results in underdeveloped external genitalia, with an elevated testosterone-to-dihydrotestosterone ratio after hCG stimulation. Meanwhile, 17β-hydroxysteroid dehydrogenase type 3 (17β-HSD3) deficiency, an autosomal recessive defect affecting the final step of testosterone production, commonly presents with a low testosterone-to-androstenedione ratio. It appears as a female phenotype at birth, with virilisation and gynaecomastia at puberty, and can mimic PAIS if androstenedione is not measured during hCG testing. When available, *AR* gene sequencing offers a definitive diagnosis of AIS and has important implications for genetic counselling of female carriers in the family. In our case, diagnosis was based on karyotype, biochemical, radiological, and histological findings; molecular confirmation was not performed, which is a recognised limitation. Gonadectomy in PAIS serves more than cosmetic purposes. The risk of malignancy in partial androgen insensitivity syndrome is significantly higher than in the complete form. Therefore, prophylactic gonadectomy after puberty, followed by hormone replacement therapy to maintain bone density, is broadly advised for high-risk groups. Although our patient's gonads showed no signs of cancer, this cannot be assumed: in a previous report, one of two similar PAIS patients who underwent bilateral orchiectomy was found to have a mixed germ cell tumour on histology. Thus, histological analysis of the removed gonad is crucial, as it can reveal hidden malignancies.

6.3. Role of the Pathologist in Multimodal Integration

Both cases highlight a key point: imaging alone may misjudge anatomy. In Case 1, "hydrometrocolpos" was not confirmed, and structures thought absent during laparoscopy were found microscopically. Karyotype indicated a virilised female in Case 1 and an under-virilised male in Case 2, but without explanation. The detailed gonadal and ductal histology, further clarified by WT1 and PAX8 immunohistochemistry in Case 1, revealed the true underlying reproductive structure in each patient. Practically, this argues for a few things: representative and generously sampled gonadal biopsies, since ovarian and testicular tissue can coexist within a single gonad and a small biopsy can miss one component; systematic examination and reporting of every ductal structure, since Wolffian and Müllerian derivatives can coexist asymmetrically and each carries mechanistic meaning; documentation of germ cell presence, maturation and any atypia, given the malignancy implications; and early involvement of the pathologist in the multidisciplinary discussion rather than at the end of it. The informatics implication is that pathology should not be treated as a terminal report appended to an otherwise complete diagnostic record. Specimen provenance, side-specific anatomy, microscopic observations, immunohistochemical results, and malignancy assessment should remain directly linked to the clinical and imaging context that generated the specimen. This linkage is particularly important when small biopsies may not represent the entire gonad.

6.4. Longitudinal Care and Patient Autonomy

DSD management may extend from childhood evaluation through adolescence and adulthood, with changing priorities that include anatomy, puberty, fertility, gonadal malignancy risk, sexual health, endocrine replacement, reproductive planning, and transitions between services. A longitudinal informatics architecture can preserve continuity across these transitions. It should support, rather than automate, multidisciplinary reasoning and shared decision-making. In particular, the system should not infer gender identity from karyotype or anatomy or convert a recommendation into an automatic indication for irreversible surgery.

7. Limitations

This report describes only two patients and therefore cannot establish causal relationships or estimate prevalence, diagnostic accuracy, or treatment outcomes. Neither case had molecular confirmation: *SRY* status was not determined in Case 1 and *AR* sequencing was not conducted in Case 2. The Case 2 hormone panel contained incompletely specified measurements, and extended follow-up was unavailable for Case 1, where retained gonads require ongoing monitoring. The initial clinical label for Case 1 (ovotesticular DSD) has been revised to 46, XX testicular DSD on histological grounds, recognising that precise DSD nomenclature depends on the demonstrated tissue composition and broader genetic context.

8. Conclusion

Two patients with superficially similar atypical genital development had distinct chromosomal, anatomical, hormonal, gonadal, and clinical profiles. Case 1 involved a 46, XX child reared as male with bilateral testicular-type tissue, absent germ cells in the sampled gonads, a right vas deferens with epididymis, and a left Müllerian-derived tubal structure supported by WT1 and PAX8 immunohistochemistry. Case 2 involved a 46, XY patient reared as female with male-range testosterone, absent Müllerian organs, preserved Wolffian derivatives, bilateral testes, and a clinical diagnosis of partial androgen insensitivity syndrome. In both cases, the decisive interpretation emerged from integration of multiple evidence streams rather than from a single test. From a medical-informatics perspective, the central requirement is a longitudinal, provenance-aware, uncertainty-sensitive record linking clinical examination, laboratory testing, imaging, surgery, pathology, immunohistochemistry, genetics, counselling, patient preference, and follow-up. Such a record can improve communication, support safer transitions across the life course, preserve uncertainty, and maintain patient autonomy while supporting diagnostic and clinical rigour.

9. Disclosure Statements

9.1. Author Contribution

NBM: Conceptualization, Methodology, Investigation, Data curation, Formal analysis, Writing – original draft, Writing – review and editing; **NR:** Investigation, Data curation, Formal analysis; **NN:** Investigation, Data curation, Writing – review and editing; **RG:** Final approval of the manuscript. NBM is the corresponding author and was responsible for overall coordination of the manuscript. All authors reviewed and approved the final version of the manuscript.

9.2. Declaration of Generative AI

The authors used generative artificial intelligence tools solely for language editing and grammatical correction. The AI tools did not contribute to the study design, data collection, analysis, interpretation, or generation of scientific content. All content has been reviewed and approved by the authors, who take full responsibility for the integrity and accuracy of the work.

9.3. Ethics approval (for clinical/animal studies)

This study presents two clinical case reports based on retrospective review of patient records. Formal institutional ethics committee approval was not required in accordance with applicable institutional policies governing case reports. Informed consent for publication of anonymized clinical information was obtained from the adult patient and the parent or legal

guardian of the pediatric patient. All patient-identifying information was excluded to protect confidentiality.

9.4. Informed Consent Statement

Written informed consent for the publication of anonymized clinical data, including medical history, laboratory findings, imaging results, genetic information, and histopathological findings, was obtained from the adult patient and the parent or legal guardian of the pediatric patient. Patient confidentiality and privacy were maintained throughout the study, and all personally identifiable information was excluded from the manuscript.

9.5. Data Availability Statement

All data generated or analysed during this study are included in this published article. Additional information is available from the corresponding author upon reasonable request, subject to patient confidentiality and institutional policies.

9.6. Acknowledgment

The authors gratefully acknowledge the All-India Institute of Medical Sciences (AIIMS), Nagpur, Maharashtra, India, and the Kidwai Memorial Institute of Oncology, Bengaluru, Karnataka, India.

9.7. Funding Statement

The authors declare that no external funding was received for this study.

9.8. Conflicts of Interest

The authors declare that they have no conflicts of interest related to this study.

9.9. Corresponding Author Contact Information

The corresponding author Dr. Nisha Bhaskar Meshram can be contacted via email drnisha[at]aiimsnagpur.edu.in.

9.10. Supplementary Information

No supplementary information or additional files are associated with this manuscript.

9.11. Sustainable Development Goals (SDGs)

This article contributes to the following Sustainable Development Goals (SDGs):

SDG 3	Good Health and Well-being
SDG 9	Industry, Innovation and Infrastructure

9.12. ORCID Information

Nisha Bhaskar Meshram	0000-0001-6949-6399
Neha Rastogi	0009-0002-9611-8697
Nilesh Nagdeve	0000-0001-7950-0988
Rasika Gadkari	0000-0001-7418-7443

9.13. Handling Editor Information

This manuscript was handled and edited by **Dr. Chandrabose Selvaraj**. Editor contact email: jomi[at]aayvu.com

10. References

Abushaala NM, Elfituri AM, Zulkifli SZ. (2021), Histological study of gonadal tissues of adult Artemia salina (Linnaeus 1758) and immunohistochemistry by Caspase 3 and HSP70 to detect specific apoptosis markers on gonadal tissues after exposure to TBTCl, *Open Vet J,* 11(1):112-120. **doi:**10.4314/ovj.v11i1.17. **PMID:** 33898292.

AlSaad R, Abd-Alrazaq A, Boughorbel S, Ahmed A, Renault MA, Damseh R, Sheikh J. (2024), Multimodal Large Language Models in Health Care: Applications, Challenges, and Future Outlook, *J Med Internet Res,* 26:e59505. **doi:**10.2196/59505. **PMID:** 39321458.

Crowe S, Cresswell K, Robertson A, Huby G, Avery A, Sheikh A. (2011), The case study approach, *BMC Med Res Methodol,* 11:100. **doi:**10.1186/1471-2288-11-100. **PMID:** 21707982.

Gangaher A, Chauhan V, Jyotsna VP, Mehta M. (2016), Gender identity and gender of rearing in 46 XY disorders of sexual development, *Indian J Endocrinol Metab,* 20(4):536-41. **doi:**10.4103/2230-8210.183471. **PMID:** 27366722.

Hsu W, Gonzalez NR, Chien A, Pablo Villablanca J, Pajukanta P, Vinuela F, Bui AA. (2015), An integrated, ontology-driven approach to constructing observational databases for research, *J Biomed Inform,* 55:132-42. **doi:**10.1016/j.jbi.2015.03.008. **PMID:** 25817919.

Jensen CFS, Wang D, Mamsen LS, Giwercman A, Jorgensen N, Fode M, Ohl D, Dong L, Hildorf SE, Pors SE, Fedder J, Ntemou E, Andersen CY, Sonksen J. (2022), Sertoli and Germ Cells Within Atrophic Seminiferous Tubules of Men With Non-Obstructive Azoospermia, *Front Endocrinol (Lausanne),* 13:825904. **doi:**10.3389/fendo.2022.825904. **PMID:** 35721721.

Kim KS, Kim J. (2012), Disorders of sex development, *Korean J Urol,* 53(1):1-8. **doi:**10.4111/kju.2012.53.1.1. **PMID:** 22323966.

Knutsen KR, Sico R, Hailemichael E, Lombard C, Lakhani DA. (2026), Zinner syndrome: Case report and brief review of the literature, *Radiol Case Rep,* 21(3):1279-1282. **doi:**10.1016/j.radcr.2025.12.004. **PMID:** 41551093.

Krzyscin M, Brodowska A, Furtak G, Pietrzyk D, Zajac K, Oder B, Przepiera A, Sowinska-Przepiera E. (2025), Partial Androgen Insensitivity Syndrome and Congenital Adrenal Hyperplasia-A Case Report of the Coexistence of Two Rare Diseases in One Patient, *Reports (MDPI),* 8(4) **doi:**10.3390/reports8040212. **PMID:** 41283580.

Lafta MS, Mwinyi J, Affatato O, Rukh G, Dang J, Andersson G, Schioth HB. (2024), Exploring sex differences: insights into gene expression, neuroanatomy, neurochemistry, cognition, and pathology, *Front Neurosci,* 18:1340108. **doi:**10.3389/fnins.2024.1340108. **PMID:** 38449735.

Lee PA, Houk CP, Ahmed SF, Hughes IA. (2006), Consensus statement on management of intersex disorders, *Pediatrics,* 118(2):e488-500. **doi:**10.1542/peds.2006-0738. **PMID:** 16882788.

Merino M, Del Barrio J, Nuno R, Errea M. (2024), Value-based digital health: A systematic literature review of the value elements of digital health care, *Digit Health,* 10:20552076241277438. **doi:**10.1177/20552076241277438. **PMID:** 39403712.

Pearce M, DeMartino L, McMahon R, Hamel R, Maloney B, Stansfield DM, McGrath EC, Occhionero A, Gearhart A, Caggana M, Tavakoli NP. (2016), Newborn screening for congenital adrenal hyperplasia in New York State, *Mol Genet Metab Rep,* 7:1-7. **doi:**10.1016/j.ymgmr.2016.02.005. **PMID:** 27331001.

Rajendiran P, Jaafar F, Kar S, Sudhakumari C, Senthilkumaran B, Parhar IS. (2021), Sex Determination and Differentiation in Teleost: Roles of Genetics, Environment, and Brain, *Biology (Basel),* 10(10) **doi:**10.3390/biology10100973. **PMID:** 34681072.

Sim JA, Huang X, Horan MR, Stewart CM, Robison LL, Hudson MM, Baker JN, Huang IC. (2023), Natural language processing with machine learning methods to analyze unstructured patient-reported outcomes derived from electronic health records: A systematic review, *Artif Intell Med,* 146:102701. **doi:**10.1016/j.artmed.2023.102701. **PMID:** 38042599.

Speiser PW, Azziz R, Baskin LS, Ghizzoni L, Hensle TW, Merke DP, Meyer-Bahlburg HF, Miller WL, Montori VM, Oberfield SE, Ritzen M, White PC, Endocrine S. (2010), Congenital adrenal hyperplasia due to steroid 21-hydroxylase deficiency: an Endocrine Society

clinical practice guideline, *J Clin Endocrinol Metab,* 95(9):4133-60. **doi:**10.1210/jc.2009-2631. **PMID:** 20823466.

Syryn H, Van De Vijver K, Cools M. (2023), Ovotesticular Difference of Sex Development: Genetic Background, Histological Features, and Clinical Management, *Horm Res Paediatr,* 96(2):180-189. **doi:**10.1159/000519323. **PMID:** 34469891.

Taberna M, Gil Moncayo F, Jane-Salas E, Antonio M, Arribas L, Vilajosana E, Peralvez Torres E, Mesia R. (2020), The Multidisciplinary Team (MDT) Approach and Quality of Care, *Front Oncol,* 10:85. **doi:**10.3389/fonc.2020.00085. **PMID:** 32266126.

Taweevisit M, Manotaya S, Thorner PS. (2013), Cystic malformation of lower female genital tract resulting in hydrops fetalis: a case report, *Pediatr Dev Pathol,* 16(1):39-44. **doi:**10.2350/12-07-1223-CR.1. **PMID:** 23113723.

Tseng HH, Wei L, Cui S, Luo Y, Ten Haken RK, El Naqa I. (2020), Machine Learning and Imaging Informatics in Oncology, *Oncology,* 98(6):344-362. **doi:**10.1159/000493575. **PMID:** 30472716.

Vasilescu S, Vasilescu DI, Dan AM, Munteanu O, Enyedi M, Slavu IM, Cirstoiu MM. (2024), Comprehensive Review of the Psychosocial Impact on Parents of Newborns With Congenital Heart Disease: A Significant Problem in Low- and Middle-Income Countries, *Cureus,* 16(9):e68532. **doi:**10.7759/cureus.68532. **PMID:** 39364504.

Wang F, Wang D, Li J, Xing N. (2026), Clinical Characteristics and Management of Two Cases of Complete Androgen Insensitivity Syndrome With Germ Cell Tumors, *Cancer Rep (Hoboken),* 9(2):e70491. **doi:**10.1002/cnr2.70491. **PMID:** 41725111.

Wang L, Zuo K. (2022), Medical Data Classification Assisted by Machine Learning Strategy, *Comput Math Methods Med,* 2022:9699612. **doi:**10.1155/2022/9699612. **PMID:** 36124172.

Wong WY, Wong LM, Tam YH, Luk HM. (2023), A Baby With Complete Androgen Insensitivity Syndrome and the Fortuitous Discovery of 45,X/46, XY Mosaicism, *Cureus,* 15(8):e43352. **doi:**10.7759/cureus.43352. **PMID:** 37700992.

Language Policy from Publisher: The publisher, editors, and reviewers are not responsible for the accuracy, completeness, or appropriateness of the language, grammar, spelling, or style used in this article. The content, including all linguistic and stylistic elements, is the sole responsibility of the authors. Aayvu Publications Private Limited does not provide language editing services, and the authors are solely responsible for ensuring that their manuscript is linguistically accurate and professionally presented prior to submission. The publisher has made no guarantees regarding the language quality of the manuscript and shall not be held liable for any misunderstanding, misinterpretation, or consequences arising from language or grammatical issues. It is the author's duty to ensure that the manuscript meets accepted scholarly and professional communication standards before submission.

Publisher Note: The content of this article, including all statements, opinions, interpretations, data, findings, conclusions, and claims, is solely the responsibility of the author(s). All claims expressed in this article are solely those of the author(s) and do not necessarily represent the views or policies of their affiliated institutions, funding organizations, the publisher, the editors, the editorial board, or the reviewers. Publication in the Journal of Medico Informatics **(JoMI) (ISSN: 3108-2696 (Online))** does not constitute verification, endorsement, approval, or validation of the scientific accuracy, completeness, reliability, or applicability of the information, methods, data, analyses, or conclusions presented. The publisher remains neutral with respect to jurisdictional claims in published maps and institutional affiliations, and regarding matters relating to gender, sex, race, ethnicity, religion, culture, disability, age, sexual orientation, gender identity, or other aspects of diversity and inclusion. Any product, service, software, technology, method, or process evaluated or discussed in this article, or any claim made by its manufacturer or other third party, is neither guaranteed, endorsed, recommended, nor warranted by the publisher. To the fullest extent permitted by applicable law, the publisher disclaims responsibility and liability for any loss or damage arising from the use of, or reliance upon, the content of this article. The publisher assumes no responsibility for the accuracy, completeness, or reliability of any such claims beyond the peer-review and editorial processes applied to the manuscript.

Open Access License: This article is an open access article distributed under the terms of the Creative Commons Attribution 4.0 International License (http://creativecommons.org/licenses/by/4.0/), which permits unrestricted use, sharing, adaptation, distribution, and reproduction in any medium or format, provided appropriate credit is given to the original author(s) and the source, a link to the license is provided, and indication of changes (if any) is made.

How to Cite: Meshram, N. B., Rastogi, N., Nagdeve, N., & Gadkari, R. (2026). Multimodal clinical informatics in disorders of sex development: A two-case study of diagnostic integration and patient-centered decision-making. ***Journal of Medico Informatics***, 02(04): 01–08. **doi:** https://doi.org/10.64659/jomi/241862